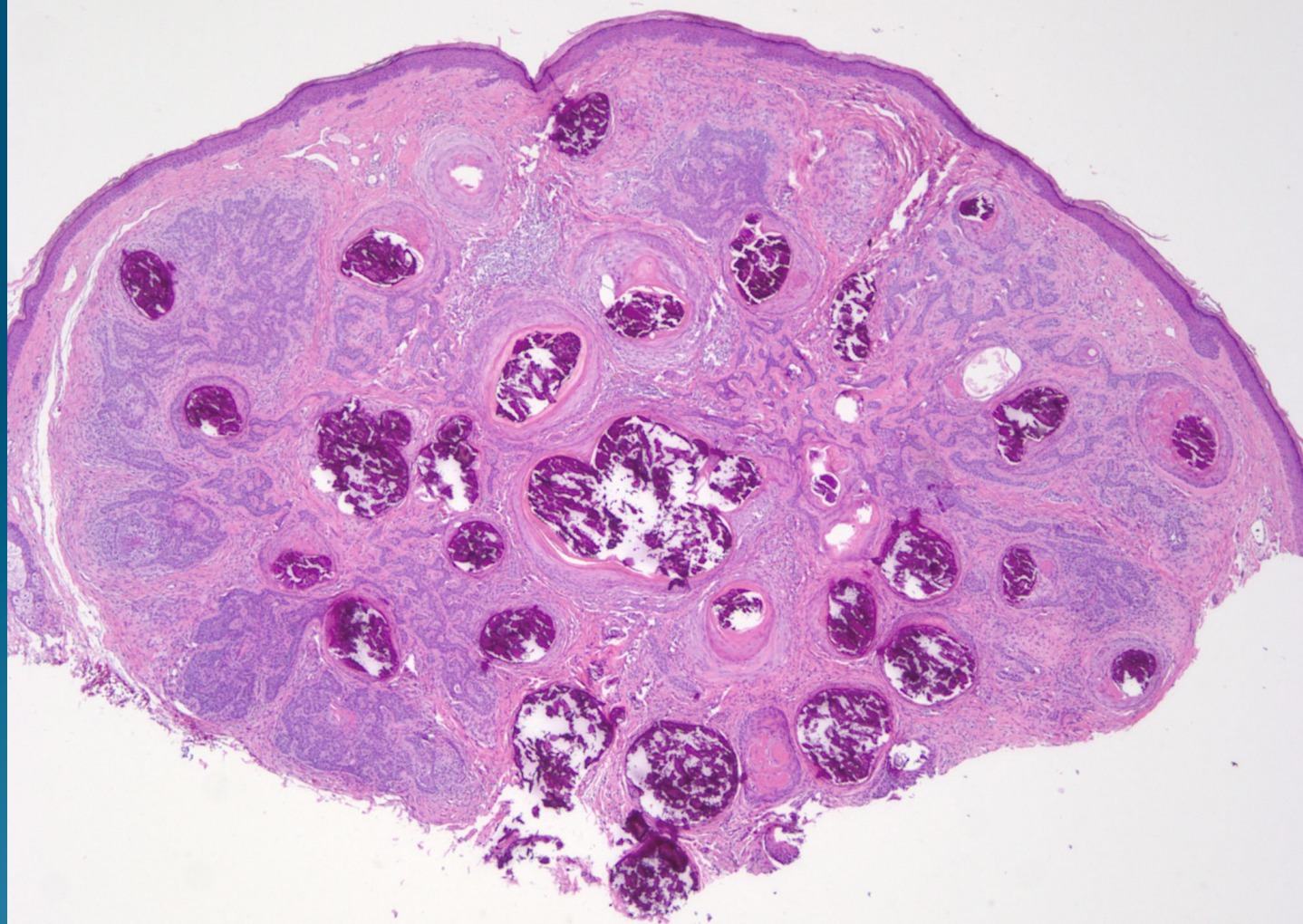
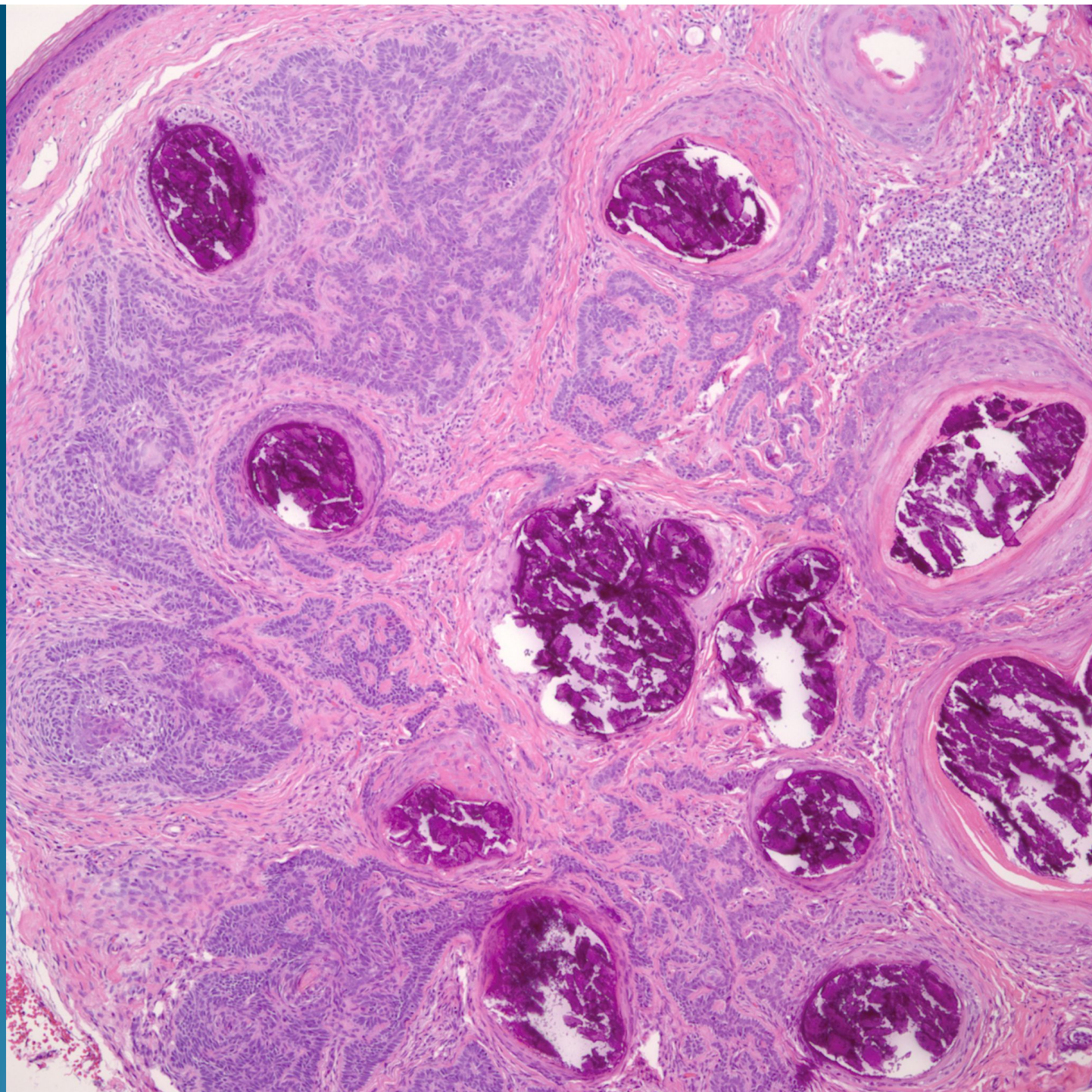
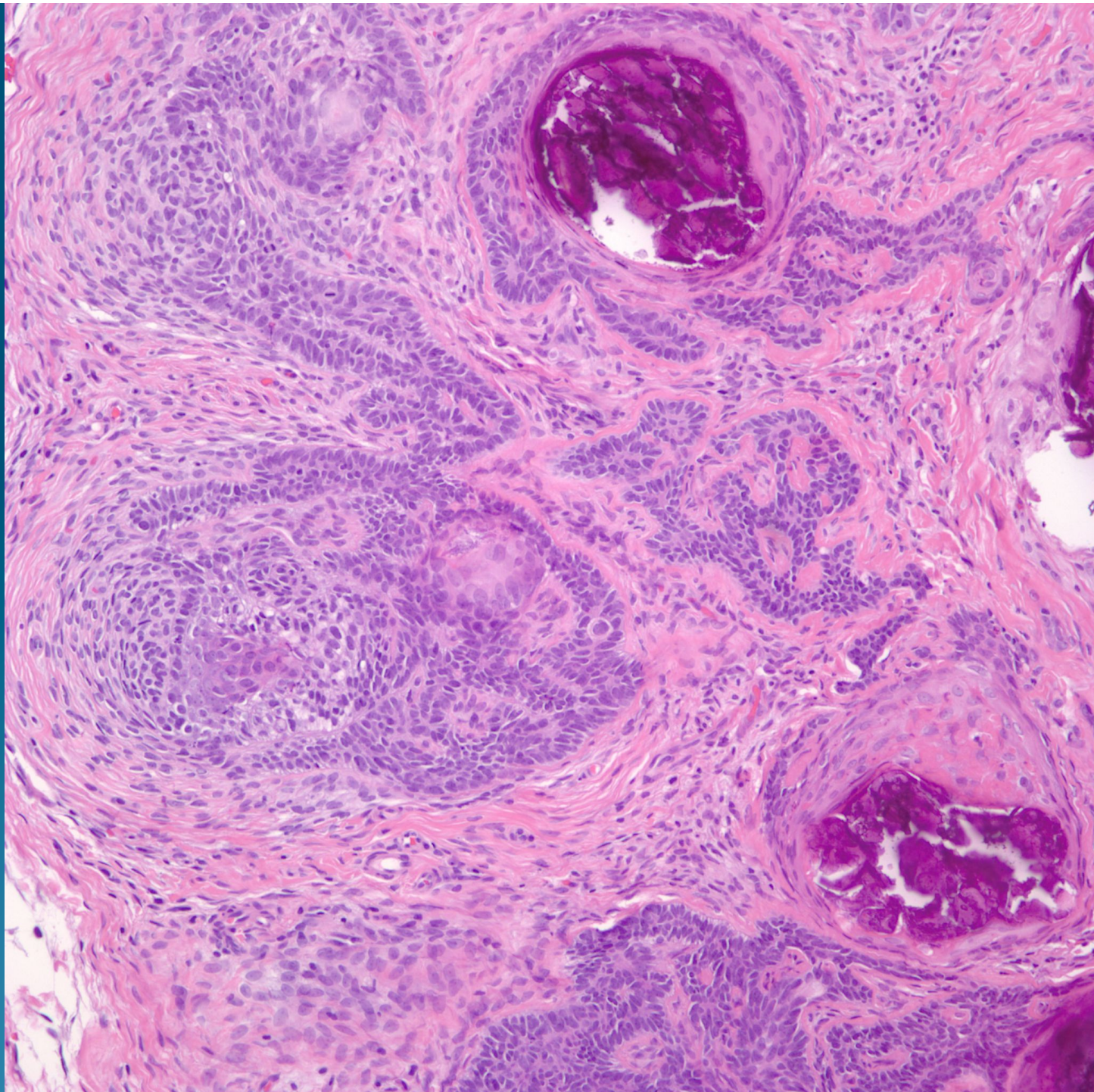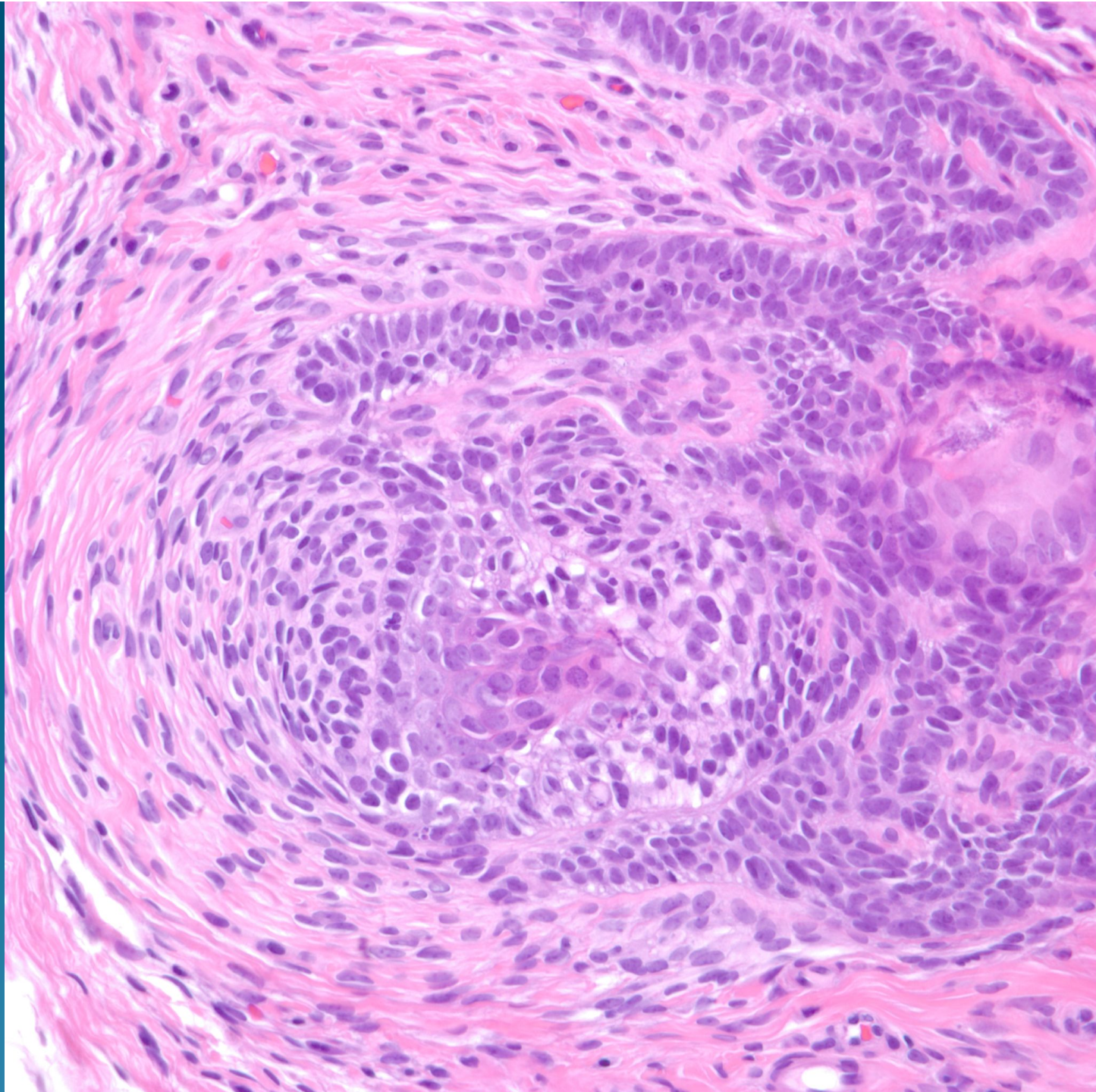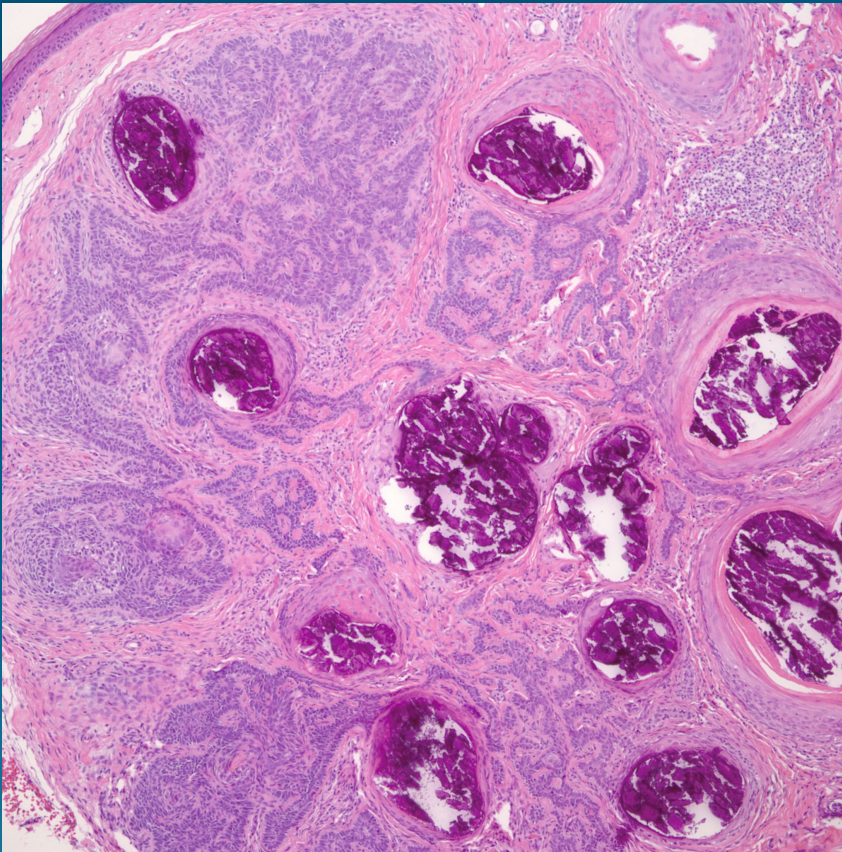
# What is the best diagnosis?

- A. Basal cell carcinoma
- B. Pilomatricoma
- C. Trichofolliculoma
- D. Inverted follicular keratosis
- E. Trichoepithelioma

# Trichoepithelioma



# Pearls



- Dermal circumscribed tumor with minimal epidermal attachment
- May have multiple follicular cysts with calcifications
- Stromal-stromal clefting but usually lacks stromal-epithelial clefting
- Look for papillary-mesenchymal bodies (primitive hair follicles)